AUTHOR'S ABSTRACT OF THIS PAPER ISSUED
BY THE BIBLIOGRAPHIC SERVICE, JUNE 1

ON THE DEVELOPMENT OF THE NERVE ENDORGANS IN THE EAR OF TRIGONOCEPHALUS JAPONICUS

TOKUYASU KUDO

Anatomical Institute, Medical High School, Nügata, Echigo, Japan

ONE PLATE

The endorgans of the auditory nerve in reptiles have been investigated morphologically with considerable thoroughness. Many authors have interested themselves particularly in the macula neglecta (described for the Amphibia by Deiters in 1862 and given the name now in common use by Retzius) and this endorgan has been studied in various vertebrates, especially in the fishes, the Sauropsida, the mammals and even in man.

Relatively few embryological investigations, however, have been published on this subject. Concerning the genesis of the macula neglecta, Retzius and Alexander concluded that this organ originates from the crista acustica posterior, the former basing his opinion on its comparative anatomy and the latter on observations of its innervation. In Hertwig's Handbuch Krause briefly states that a small region of common neuroepithelium differentiates upon the separation of the saccular from the utricular portions. Fleissig, who, working on reptiles (Gecko), was the first to investigate extensively the development of the macula neglecta, disagrees with both of these statements and is of the opinion that the organ arises from the macula sacculi. The same conclusion is reached by Okagima in the case of Hynobius; but this author remarks that because in the Amphibia the macula neglecta lies within the sacculus, its origin in these forms is easier to determine than in the reptiles, where the macula is found in the utriculus. Corroboration of this view, according to which the macula neglecta arises from the neuroepithelium of the pars inferior, is found in Okagima's study of the salmon embryo and Wenig's recent work on Pelobates fuscus.

This simple interpretation of the genesis of the macula neglecta has been considerably complicated by the studies of P. and F. Sarasin, who claim to have found a second endorgan in the Caecillidae, for they distinguish two different maculae, one of which lies in a small evagination of the sacculus (macula neglecta of Retzius), the other in the floor of the utriculus (macula neglecta fundi utriculi). The existence of the latter was, however, denied by Retzius, in which opinion he is joined by Ayers. Retzius states: "Es geht nicht hervor, dass die am Boden des Utriculus der Caeciliiden gefundene Nervendstelle einer neu entdeckten Nervendstelle entspricht. Denn gerade am Boden des Utriculus liegt die von mir bei vielen Fischen, Reptilien und Vögeln entdeckte Nervendstelle, Welche von mir schon längst 'Macula neglecta' genannt wurde. Es ist deshalb ganz unrichtig, wenn die Herren Sarasin die von ihnen bei Ichthyophis am Boden des Utriculis beschriebene Nervendstelle als von ihnen neu entdeckt bet achten und sie als eine 'Macula fundi utriculi' aufführen. Die echte 'Macula neglecta' liegt am Boden des Utriculus oder Öffnung des Canalis utriculo-saccularis, oder auch-nach meiner Ansicht—bei den niederen Amphibien in der eigentümlichen Ausstülpung dieses Canalis, welches ich 'Pars neglecta' gennannt habe, bei den höheren aber in einer von ihm abgetrennten Ausstülpung der Sacculuswand." He adds that it would be interesting to know whether both of the endorgans as described by P. and F. Sarasin really do occur, in view of the fact that in all Amphibia that have been thoroughly studied a single macula neglecta occurs. Ayers contends that the new endorgan of the Sarasins is probably none other than the macula neglecta of Retzius. But Fleissig, from his study on the development of the labyrinth in Gecko, was able to demonstrate a transitional condition between the two described above. According to this author the macula neglecta of Retzius is to be regarded as a persisting organ in the sinus inferior, while only traces of the macula neglecta of the Sarasins occurs in adult individuals; and these traces may well be regarded as vestiges of Sarasin's macula, which is present as a developing organ only at a certain stage.

To this much mooted and interesting question, then, I wish to contribute the modest results which I have been able to obtain from my study of Trigonocephalus japonicus.

The viperid embryos which were placed at my disposal comprise more than 27 stages[1] (Suzuki-Okajimas series), of which I have employed four for the present study. The embryos were fixed in formol-alcohol, potassium bichromate-acetic and corrosive sublimate-acetic and were stored in alcohol until stained and imbedded in paraffin. Mainly frontal sections 10–15μ thick were made through the heads of the embryos. These were stained in toto with alcoholic borax carmine and Weigert's iron haematoxylin, and in the latter case orange G was employed as a counter stain. The two adult specimens were fixed in potassium bichromate, imbedded in celoidin and cut vertically through the head. These sections, 30μ thick, were stained in haematoxylin-eosin and orange G.

Stage 1 (fig. 1). The embryo is coiled up in 4½ turns. Olfactory pit very deep. Wall of optic cup thickened anteriorly; lens solid. Fixation: corrosive-acetic. Stain: Weigert's iron haematoxylin; sections 15μ. Frontal sections of head and body.

The auditory vesicle, which is distended into a sac-like structure, is already oval in shape and, since it runs through 47 sections, is about 0.705 mm. in antero-posterior diameter. It lies some distance removed from the brain. Differentiation in the epithelial lining of the wall of the auditory vesicle is already apparent. Laterally the epithelium is flattened, while the medial and lower walls are stratified several cells deep and show here and there a mitotic figure. This thickened portion represents the common neuroepithelium which will later separate into the pars superior and the pars inferior. The ductus endolymphaticus is already tubular in form, with the dilated saccus endolymphaticus at the end.

Stage 2 (fig. 2) The embryo consists of 3½ coils. The parietal elevation is prominent. The lens is approximately as in the preceding stage; the retina moderately pigmented. The

[1] The number includes 7 sectioned by the writer.

pocket-shaped olfactory pit is deep and the oral sinus deeply cleft. Fixation: formol-alcohol. Stain: alcoholic borax carmine. Sections 15μ in thickness cut frontally through head and entire body. The antero-posterior diameter of the auditory vesicle is calculated to be 0.48 mm., since it runs through 32 sections.

The auditory vesicle has at this stage undergone considerable development. The pars superior and the pars inferior are distinctly separated. The anterior and the posterior semicircular canals are now completely constricted off; but this is not the case with the lateral canal; i.e., this canal is not yet independent of, but still broadly in communication with the main lumen of the vesicle. The pars inferior is well differentiated and possesses an elongated oval swelling on the ventro-medial wall of the vesicle. The ductus endolymphaticus appears as a long slender tube.

In correspondence with the external change in form the epithelial lining is also well differentiated. The anterior canal, which is flattened in a medio-lateral (partly dorso-ventral) direction, widens out at its anterior end into an ampulla, and the crista acustica anterior is here represented by high epithelium which is continuous, without any decrease in thickness, with the macula utriculi. The same holds true for the crista lateralis, the epithelium of which is somewhat lower than that of the anterior crista. The medial and ventral walls of the utriculus are made up of especially high stratified epithelium, which, bending upon itself at the entrance of the pars inferior, passes over into this without any sharp boundary line. The tallest epithelium of the medial wall decreases somewhat in thickness as it passes over into the medial wall of the endolymphatic duct. The flattened lateral wall of the utriculus presents no points of especial interest. The crista posterior has moved back some distance and appears as a thickened zone of cells in several layers at the ventro-medial portion of the semicircular canal.

Stage 3 (fig. 3) The embryo consists of about $2\frac{1}{2}$ coils. On the surface of the body striations are observed which are transverse on the ventral and crossed on the dorsal surface. Fixation: Corrosive-acetic. Stain: alcoholic borax carmine.

The 15 sections cut frontally through head and body. The membranous labyrinth runs through 102 sections and hence has an antero-posterior diameter of 1.53 mm.

The utriculus and the sacculus communicate by a narrow foramen, the canalis utriculo-saccularis; the lateral semicircular canal is now an independent structure. Each nerve endorgan is well developed. The crista anterior is mound-shaped; the crista lateralis is a thick cell mass which appears as a crescent in the sections. Both structures still maintain their connection with the crista utriculi.

The tall epithelium of the utricular froor, which diminishes in thickness as it passes upward, doubtless represents the first anlage of the macula neglecta Retzii. It is continuous with the macula partis inferioris through the still cylindrical epithelium of the canalis utriculo-saccularis. The macula partis inferior consists in this stage of an extended zone of neuroepithelium on the medial wall of the pars inferior and already there is to be seen on its margin several minimal though unmistakable points devoid of nuclei. The fine nerve-fiber bundles that arise from the ganglion acusticum show excellent mitotic figures where the fibers enter the macula. The low cylindrical epithelium of the ductus endolymphaticus is continuous with the tall neuroepithelium of the medial wall of the sacculus.

Stage 4 (fig. 4). The embryo, which is made up of $2\frac{1}{2}$ coils, has the appearance of a fully developed individual. Its peculiar dermal spots are prominently displayed over the entire body. Fixation: formol. Stain: Alcoholic borax carmine. Sections: 15 μ in thickness, cut frontally through the head.

The nerve endorgans are nearly all differentiated and on each the marginal zone free of nuclei may be recognized. The cristae anterior and posterior are separated from the macula utriculi by a low epithelium.

It is worthy of notice that the thick epithelium of the utricular wall shows clearly a border without nuclei and that it is differentiated from the epithelium of the canal by its greater thickness. It soon becomes thinner as it passes gradually over into the undifferentiated epithelium lining the vesicle. This thickening just

referred to may well be considered as the first anlage of the macula neglecta Retzii. In the wall of the canal there is no zone marked out by a cell-free border, although the epithelium is still rather thick, and this in turn is continuous with the mound-shaped swelling, the macula sacculi.

Corresponding to the external changes in form, the macula partis inferioris is now separated into the papillae basilaris and lagenae, which are still united by cubical epithelium. The crista posterior is quite separated from the macula sacculi by an unspecialized epithelium.

Stage 5. The embryo consists of $2\frac{1}{2}$ coils. The external characters are quite comparable to those of the preceding stage. Fixation: potassium bichromate. Stain: alcoholic borax carmine. The 15 μ sections are cut frontally through the head.

The macula neglecta Retzii, which lies closely adjoining the canalis utriculo-saccularis, is mound-shaped and consists of two or three layers of cells. The maculae neglecta and sacculi are united by means of cubical epithelium except in the wall of the canal, where the epithelial cells are still tall.

The Adult Animal (fig. 5). Fixation in potassium bichromate-acetic. Stain: haematoxylin-eosin and haematoxylin-orange G. The section are cut frontally through the head.

Among the endorgans the cristae anterior and posterior are composed of two- to three-layered epithelium and project as rounded protuberances into the lumen. The macula utriculi lies on the anterior-medial wall of the utriculus and is composed of auditory and supporting cells. The macula neglecta appears as a swelling in the proximity of the canalis utriculo-saccularis on the floor of the utriculus; its vesicular auditory cells rest upon one or two layers of supporting cells. The macula diminishes in thickness as it passes over into the simple cylindrical epithelium which makes up the wall of the canal and which is continued beyond in the wall of the sacculus. The tall epithelium found on the medial wall of the canal is also to be seen on and near the lateral wall. In several places within and near the canal the lining is thrown up into wave-like folds.

DISCUSSION

The results of my studies, as presented above, agree on the origin of the macula neglecta with the view of Fleissig, for it has been shown that this macula is derived directly from the macula partis inferioris. Even after the neuroepithelium has been completely separated by the undifferentiated epithelium from the pars inferioris, the macula neglecta remains for a long time in connection with the macula sacculi.

The common neuroepithelium on the ventro-medial wall of the auditory vesicle of stage 1 begins to divide into the utricular and the saccular portions (stage 2), the histological changes in the epithelium keeping pace with the external changes in form. The more strictly utricular portion swells to form the crista anterior, crista lateralis and macula utriculi, which are united by means of a tall epithelium. The more strictly saccular portion, separated from the utricular portion by flattened epithelium (stage 3) still extends from the medial wall of the canalis utriculo-saccularis upwards further into the floor of the utriculus.

After the macula saccularis has been differentiated (stage 3) the macula neglecta gradually protrudes more and more into the lumen and in stage 4 discloses a border free of nuclei, but is still connected by means of a cubical epithelial layer with the macula sacculi. Furthermore, the crista ampullaris posterior becomes entirely free from the saccular portion, while the papillae basilaris and lagenae still maintain their connection with the macula saccularis by means of a bridge of cubical epithelium. In stage 5 the well developed macula neglecta may be seen as a mound-shaped structure as in adult specimens.

The existence of two maculae neglectae I have failed to demonstrate in my Trigonocephalus material, although I have minutely examined the rather comprehensive series of the different stages. Fleissig says: "1) die macula sacculi, welche nicht mehr die ganze mediale Sacculuswand, sondern nur mehr deren unteresten Abschnitt einnimmt. Ein Epithel, das etwas höher ist als das indifferente Wandepithel und ganz typisch in der Umgebung der Nervendstellen vorkommt, erstreckte sich von der Macula

sacculi nach aufwärts zum Foramen Utr.-Sacc., wo es zu einer zweiten Neuroepithelstelle—2) Macula neglecta Sarasinianschwillt, die im Foramen Utr.- sacc. (an dessen hinterem Rand) gelegen, zum kleineren Teil in den Sacculus, zum grösseren in den Utriculus hineinragt. Von dieser erstreckt sich wieder ein niedriges Epithel in den Sinus inferior hinein zu persistierenden 3) Macula neglecta (Retzii). Beide Maculae neglectae stehen auf derselben Entwicklungsstufe."

Now even if the bulging endorgan found in the floor of the utriculus of stages 4 and 5 were not to be regarded as the macula neglecta Sarasini but rather as the macula neglecta Retzii, I would not feel justified in interpreting the thickened epithelium which extends through the canalis utriculo-saccularis to the macula saccularis as the macula Sarasini. The further the development progresses the thinner does the epithelium of the inner wall of the alveus become as compared with the early stage of the auditory vesicle. One may readily see that the medial wall of the alveus communis is lined with relatively taller epithelial cells in stage 2 than in stage 3. From this it is apparent that the neuroepithelium, except where it progressively develops into nerve endorgans, is destined to be reduced to indifferent epithelium, even though the time when it retrogresses be very variable.

According to my opinion, therefore, the tall epithelium of medial wall of the canal and its proximity represents a developmental stage in the neuroepithelium which later retrogresses. If this epithelium were to be interpreted as a nerve endorgan, the tall epithelium of other regions, as e.g., of the lateral wall of the canal and the medial wall of the utriculus and the ductus endolymphaticus, would have to be regarded as neuroepithelium, since these latter regions are quite similar in structure and arrangement of their epithelial cells to those in the medial wall of the canal. At any rate, the macula neglecta does not occur in my material as it has been pictured by Fleissig in his work. But it should be noted that in the adult snake the epithelium of the canalis utriculo-saccularis and its immediate environs is relatively much thicker as compared with the medial and lateral walls.

From the above it appears, then, that the macula neglecta Retzii, which comes to lie in the floor of the utriculus, arises from the neuroepithelium of the pars inferior, as was first established by Fleissig in the case of Gecko; but, as stated above, I am unable to demonstrate in my material any progressively developing endorgan which could represent the macula neglecta Sarasini.

Alexander has suggested that in the embryo of Echidna the tall epithelium at the mouth of the ductus endolymphaticus may represent the vestige of the Amphibian macula neglecta Sarasini. This tall epithelium, which is continuous with the neuroepithelium of the medial utricular wall, Fleissig has also observed in the embryo of Gecko, but his interpretation is a totally different one, for he does not consider it remarkable that the mouth of the ductus endolymphaticus, which is still in active growth, should possess tall epithelium where it passes suddenly into the neuroepithelial anlage of the medial utricular wall.

In conclusion I desire to record the observation that the three semicircular canals of Trigonocephalus japonicus do not develop synchronously, the medial and posterior canals anticipating the lateral canal in their development.

SUMMARY

1. The macula neglecta arises directly from the macula partis inferioris.

2. The occurrence of two maculae neglectae is not to be observed in my material: while the macula neglecta Retzii is well developed, there does not form a persistent macula Sarasini nor does this endorgan even develop temporarily as in Gecko (Fleissig).

3. The anterior and the posterior semicircular canals are separated off much earlier than the lateral canal.

Kyoto, Sept. 15, 1914.

LITERATURE CITED

The references marked with an asterisk (*) were available to the author.

*ALEXANDER, G. 1900 Über Entwickelung und Bau der Pars inferior labyrinthi der höheren Wirbeltiere. Denkschr. d. k. Akad. d. Wiss. Math.-Naturw. Kl. 70.

*ALEXANDER, G. 1904 Entwickelung und Bau des inneren Gehörorgans von Echidna aculeata. Jenaische Denkschr., Bd. 6.

1904 Zur Entwickelungsgeschichte und Anatomie des inneren Gehörorgans der Monotremen. Centralbl. f. Phys. Bd. 17.

1905 Zur Frage der phylogenetischen, vicariierenden Ausbildung der Sinnesorgane (Talpa europaea und Spalax typhlus). Zeitschr. f. Psych. u. Phys. d. Sinnesorg. Bd. 38.

AYERS, H. 1892 Vertebrale Cephalogenesis. 2. A Contribution to the morphology of the Vertebrate Ear, etc. Journ. of Morph. vol. 6.

1893 The macula neglecta again. Anat. Anz. Bd. 8.

DEITERS, D. 1862 Ueber das innere Gehörorgan der Amphibien. Reichert u. Du Bois Reymonds Arch.

FLEISSIG, J. 1908 Die Entwickelung des Geckolabyrinthes. Ein Beitrag zur Entwickelung des Reptilienlabyrinthes. Anat. Hefte, Bd. 37.

KRAUSE, R. 1906 Entwickelungsgeschichte des Gehörorgans. Hertwigs Handbuch d. Vergl. u. Experim. Entw.-Lehre.

KRAUSE, R. 1906 Das Gehörorgan der Petromyzonten. Anat. Anz. Erg.-Heft 7. Bd. 29.

OKAJIMA, K. 1911 Die Entwickelung des Gehörorgans von Hynobius. Anat. Hefte. Bd. 45.

OKAJIMA, K. 1911 Die Entwickelung der Macula neglecta beim Salmoembryo. Anat. Anz. Bd. 40.

RETZIUS, G. 1878 Zur Kenntniss von dem membranösen Gehörlabyrinth bei den Knorpelfischen. Arch. f. Anat. u. Phys. Anat. Abt. Jahrg.

RETZIUS, G. 1880 Zur Kenntniss des inneren Gehörorgans der Wirbeltiere. Arch. f. Anat. u. Phys. Anat. Abt. Jahrg.

*SARASIN, P. U. F. 1890 Ergebnisse naturwissenschaftlicher Forschungen auf Ceylon. Bd. 2.

SARASIN, P. U. F. 1892 Ueber das Gehörorgan der Caeciliiden. Anat. Anz. Bd. 7.

STÜTZ, L. 1912 Ueber sogenannte atypische Epithelformation im häutigen Labyrinth.-Eine rudimentäre Mac. negl. Morph. Jahrb. Bd. 44.

WENIG, J. 1913 Untersuchungen über die Entwickelung der Gehörorgane der Anamnia. Morph. Jahrb. Bd. 45.

* WITTMAACK 1911 Ueber sogenannte atypische Epithelformation im membranosen Labyrinth. Verh. d. Deutsch. Otol. Gesell.

PLATE

PLATE 1

1 Stage 1. Stain: Weigert's Iron haematoxylin, Leitz Achromat 6; Ocular I.
2 Stage 2. Stain: Boraxcarmine. 3XI.
3 Stage 3. Stain: Boraxcarmine. 3XI.
4 Stage 4. Stain: Boraxcarmine. 3XI.
5 Adult. Stain: Haematoxylin-eosin. 1XI.

ABBREVIATIONS

C.u.s. Canalis utriculo-saccularis
B., Brain
A.v., Auditory vesicle
Lag., Lagena
L.c., Lateral semicircular canal
A.c., Anterior semicircular canal
U., Utriculus
M.n., Macula neglecta
M.s., Macula sacculi
O., Otolith
P.i., Pars inferior
P.s., Pars superior
S., Sacculus

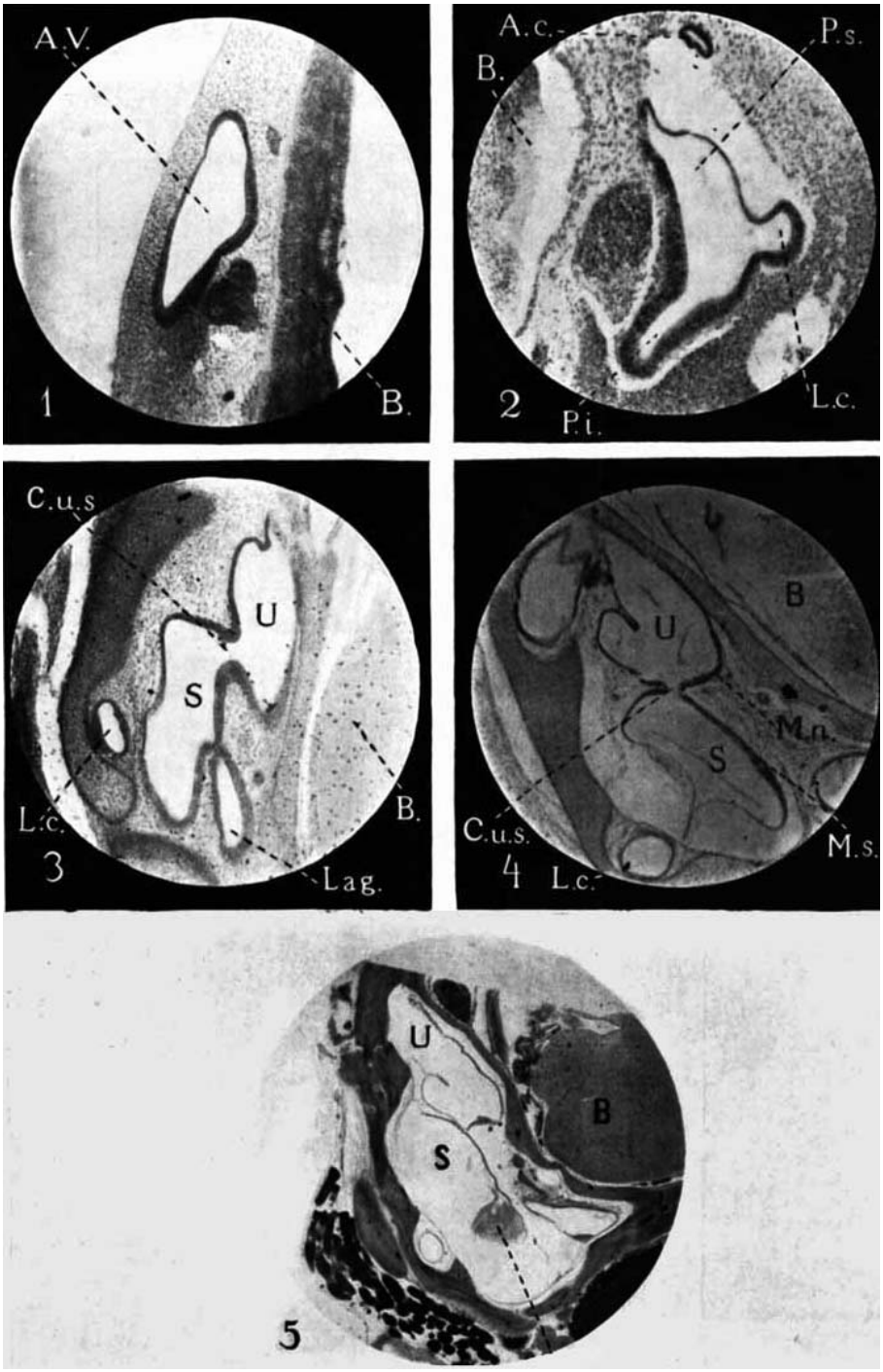
A.V.
B.
1
A.c.
P.s.
B.
2
P.i.
L.c.
C.u.s
U
S
L.c.
B.
3
Lag.
U
B
M.n.
S
C.u.s.
M.s.
4
L.c.
U
B
S
5